EMS SEO

Presents

Uncovering Difficult Airways



DISCLAIMER AND/OR LEGAL NOTICES:
The information presented herein represents the views of the author as of the date of publication. Because of the rate with which conditions change, the author reserves the right to alter and update this information based on the new conditions. The publication is for informational purposes only. While every attempt has been made to verify the information provided in this publication, neither the author nor its affiliates/partners assume any responsibility for errors, inaccuracies or omissions. Any slights of people or organizations are unintentional. If advice concerning medical, legal or related matters is needed, the services of a fully qualified professional should be sought. You should be aware of any laws/practices or local policies which govern emergency care or other pre hospital care practices in your country and state. Any reference to any person or business whether living or dead is purely coincidental.

This report is posted as a discussion of advanced practice airway management strategies for difficult and dangerously dynamic airway situations with high probability of adverse outcomes and in which experts may reasonably disagree or have preference for a different approach based on their experience, training, skill and confidence level. It does not comprehensively discuss all aspects of airway management or of care of the patient with an artificial airway. The purpose of this publication is to promote thinking and planning for such situations before they occur.

During and often times after traditional paramedic training, all pre hospital care providers will come across difficult intubations and airway management.

There is a wealth of information on many different techniques, procedures and equipment that is being used to obtain airway control and management. The important thing to remember is the basic principles and goal of airway management.

Airway control starts with effective bag-mask ventilations. This represents the foundation of all advanced airway management. All caregivers should be proficient in the delivery of effective ventilations with a bag-mask device. Bag-mask ventilations, used with an oral pharyngeal or nasal pharyngeal airway, may sometimes be the only mechanism available for effective airway control. **When all else fails remember the basics.**

For over 30 years endotracheal intubation (ETI) has been central to advanced prehospital airway management. With that said, ETI efforts are not always successful or possible. In addition, there may be situations where ETI efforts are anticipated to be difficult or futile. To ensure that every patient has a patent airway, alternate airways (non-ETI airway management devices) should be available to all prehospital emergency professionals that perform ETI.

The following has been recommended for emergency medical services (EMS) agencies that provide advanced life support level care:

All agencies should have available for use at least one blindly inserted non surgical airway device as a rescue or alternative to ETI. Examples such as Combitubes or Laryngeal Mask Airway (LMA)

Rescuers must receive adequate initial and continuing training in the use and application of alternate airways, including training in difficult airway management and decision making.

Medical directors should implement quality assurance and improvement initiatives to ensure adequate training in and appropriate clinical application of alternate airways.

Finally, the American Heart Association states that no one method or device can provide effective airway management for all patients. Therefore having several options available to control and maintain a patients airway should be a priority in all EMS systems.

As an overview, you can Click Here and view a short video on Entotracheal Intubation.

The following pages also describe basic airway techniques and ETI. It is vital that you understand the basics of airway control before you encounter a difficult airway. Knowing

the basics will help you perform better and understand why one individual's airway may be more difficult to control than another.

Airway/Breathing Basics

Introduction
Skillful, rapid, assessment and management of airway and ventilation are critical to preventing morbidity and mortality. Airway compromise can occur rapidly or slowly and may recur. Frequent reassessment is necessary. Preventable causes of death from airway problems in trauma include the following:

Failure to recognize the need for an airway. Inability to establish an airway.
Failure to recognize the incorrect placement of an airway. Displacement of a previously established airway.
Failure to recognize the need for ventilation.
Aspiration of the gastric contents.

Initial airway management at any level, but especially outside of medical treatment facilities (MTFs).
Immediate goal: Move tongue, pharyngeal soft tissues, and secretions out of airway. Until a formal airway is established, place patients in the lateral or prone position (rescue position).

Chin-lift and head tilt: Place fingers under the tip of the mandible to lift the chin outward from face.
Two-Handed Jaw Thrust: Place both hands behind the angles of the mandible and displace forward. This method can be used on the patient with cervical injury.

Oropharyngeal airway:

- Insert oral airway upright if a tongue depressor is used (preferred method).
- Keep the airway inverted past the tongue then rotate 180□.
- Too small an airway will not alleviate the obstruction. Too long an airway may fold the epiglottis caudally, worsening the obstruction.
- Estimate airway size by distance from corner of mouth to ear lobe.
- Oral airways are not used in conscious patients.

Nasopharyngeal airway.

- Pass lubricated nasal airway gently through one nostril.
- Not used in suspected facial or basal skull injuries.
- Is tolerated by conscious patients.

Field expedient.

Ventilation

Ventilate patient with bag valve mask (BVM).

 Bring the face into the mask rather than pushing the mask onto the face.

 The chin-lift and head tilt are also employed during mask ventilation unless they are contraindicated due to cervical spine precautions.

Assess air movement during mask ventilation by observing rise and fall of the chest, auscultation, absence of a mask leak, compliant feel of self-inflating bag, and stable oxygen saturation.

 If air movement is not achieved, use two-person mask ventilation (Fig. 1-1).

Fig. 1-1. Two-person mask ventilation.

♦ One person lifts the jaw aggressively at the angles of the mandible; the other holds the mask and ventilates. Alternatively, one person may lift and hold the mandible with both hands, while at the same time holding down the mask on both sides. The other person ventilates the patient.

♦ If air movement is still not present, obtain a definitive airway.

♦ Unsuccessful and aggressive attempts at ventilation may result in inflation of the stomach, placing the patient at increased risk for vomiting and aspiration.

Positive pressure ventilation can convert a simple pneumothorax into a tension pneumothorax. Perform frequent assessment and have equipment available for needle chest decompression.

Orotracheal Intubation

Rapid Sequence Intubation (RSI)—7 steps.

1. Preoxygenate with 100% oxygen by mask.
2. Consider fentanyl—titrate to maintain adequate blood pressure and effect (2.0-2.5 ∝g/kg).
3. Cricoid Pressure—Sellick maneuver until endotracheal tube (ETT) placement is confirmed and balloon is inflated.
4. Induction Agent: etomidate 0.1-0.4 mg/kg IV push.
5. Muscle Relaxant: succinylcholine 1.0-1.5 mg/kg IV push.
6. Laryngoscopy and orotracheal intubation.
7. Verify tube placement.

Direct laryngoscopy technique.

 Ensure optimal "sniffing" position is achieved unless contraindicated by cervical spine injury.
 Open the mouth by scissoring the right thumb and middle finger.
 Hold the laryngoscope in the left hand and insert the blade along the right side of the mouth , slightly displacing the tongue to the left.

♦ Macintosh (curved) blade: Advance the tip of the blade into the space between the base of the tongue and the epiglottis (valecula). Apply force at a 30□-45□ angle, lifting the entire laryngoscope/blade, without rocking it backward (Fig. 1-2).

♦ Miller (straight) blade: Advance the tip of the blade into the posterior oropharynx, picking up the epiglottis and tongue base anteriorly and laterally, and apply a force vector like that of the Macintosh blade. Avoid rocking the laryngoscope backward (Fig. 1-3).

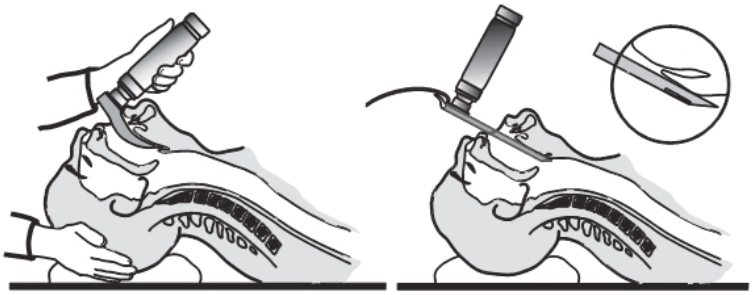

Fig. 1-2. Use of curved blade laryngoscope. **Fig.1-3**. Use of straight blade laryngoscope.

♦ Visualize the vocal cords.

Many patients will challenge your airway-management skills. The increased incidence of obesity, anatomical structure, and disease processes all contribute to an inability to provide effective airway management for your patients.

In addition, endotracheal intubation has been shown to have an unacceptably high incidence of complications when provider experience level is low or monitoring of tube placement is inadequate.

The bottom line - **THE GOAL OF DIFFICULT-AIRWAY MANAGEMENT IS TO PROVIDE EFFECTIVE OXYGENATION AND VENTILATION WHILE LIMITING COMPLICATIONS.**

Here are few techniques you can try when you come across a difficult endotracheal intubation.

When endotracheal intubation is used to control an airway, external manipulation of soft tissues of the anterior neck may assist in visualization and placement of the endotracheal tube.

The two primary methods are the **Sellick maneuver** and backward-upward-rightward pressure **(BURP).**

The **Sellick maneuver** is backward pressure on the crichoid cartilage. It is used as a method to prevent regurgitation of stomach contents.

BURP is used by exerting pressure on the thyroid cartilage. Positioning the thyroid cartilage backward, upward, and rightward is believed to improve laryngeal view with a laryngoscope.

Both of the Sellick and BURP maneuvers are done by an assistant during intubation.

Another technique is to utilize **bimanual laryngeal manipulation**, the laryngoscope operators use their right hands for laryngeal manipulation while conducting laryngoscopy. Once proper visualization is obtained, the laryngeal position is maintained by an assistant while the operator passes the endotracheal tube. A recent study demonstrates that the latter method provided the best visualization.

Two other methods you may have seen used :

Using a blanket roll behind the patient shoulders to better visualize the vocal cords

OR

Having a crew member pull up on the patients arms , thereby hyperextending the neck and making visualization better. (I wouldn't do this method with family watching since it does look a bit unconventional).

Occasionally you may visualize the vocal cords fine, and just cannot seem to advance the ET tube. Each time you try to pass through the cords the tip of the tube slides away. You can try using Magill forceps to drive the tip of the tube towards the glottis. In these situations, the choice depends on the operator's skill, experience and preferences, available devices, patient's clinical conditions, particularly oxygenation, bag and mask ventilability, difficulty grade defined with an optimal laryngoscopic attempt.

Quick Tips :

Not enough space to maneuver: Increase mandibular distraction and/or instruct someone to use gauze to pull on the tongue.

Patient too obese - cannot see : Have an assistant spread the skin of the neck laterally. This will decrease the distance from the thyroid cartilage to the skin.

♦ Consider the "BURP" maneuver when the laryngoscopic view is poor (Fig. 1-4).

♦ "Backward-Upward-Rightward-Pressure" of the larynx, also referred to as external laryngeal manipulation.

♦ Place the fingers of an assistant onto the larynx with your right hand and manipulate the glottic opening into the field of view.

♦ Assistant then holds the position for intubation.

Eschmann stylet or Gum Elastic Bougie (GEB) (Fig. 1-5).
♦ Blindly guide the tip of the stylet beneath the epiglottis, then anteriorly through the vocal cords.
♦ Advance the bougie deeply. Placement into the trachea results in the sensation of tracheal ring "clicks", and turning of the stylet as it passes airway bifurcations.

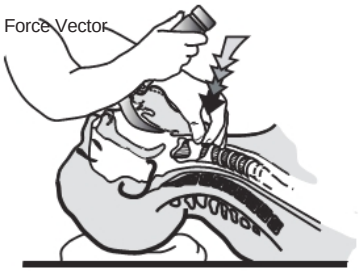

Fig. 1-4. BURP maneuver.

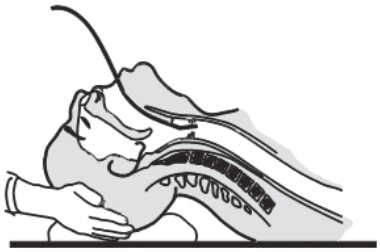

Fig.1-5. Eschmann stylet in place.

♦ The patient may cough as the stylet passes through the airway.
♦ When passed beyond the trachea, the stylet will stop at a terminal bronchus. If placed into the esophagus, it will pass indefinitely into the stomach without any tactile feedback.
♦ The ETT is guided over the stylet into the airway, and tracheal intubation is confirmed.
o Advance the ETT between the vocal cords, withdraw stylet, and advance the ETT to 20-21 cm at the teeth for adult females , 2 2 - 2 3 cm for adult males . Deeper placement may result in right mainstem intubation.
o Confirm placement of the ETT in the trachea.
o Auscultate over the axilla to ensure breath sounds are equal.

Avoid making more than 3 attempts at direct laryngoscopy. Excessive attempts may result in airway trauma and swelling, potentially turning a "cannot intubate" urgency into a "cannot intubate-cannot ventilate"emergency.

Difficult Airway

After three unsuccessful attempts at direct laryngoscopy, abandon the technique and try alternatives.

Alternative intubation techniques.

- Tactile intubation.
  - ♦ Requires no instruments.
  - ♦ No light use—good in light control situations.
  - ♦ Slide hand closest to patient over tongue to hold it down.
  - ♦ Lift epiglottis with first two fingers.
  - ♦ Slide ETT along the "v" between the two fingers into the airway.

- Lighted stylet or "light wand" intubation.
  - ♦ Flexible wand, lighted at the tip, is placed through the ETT.
  - ♦ Wand is advanced by tactile guidance into the trachea .
  - ♦ Position in trachea is verified by transillumination.
  - ♦ The ETT is advanced over the wand.

- Flexible fiberoptic oral or nasal intubation.
- Retrograde wire intubation.
- Rigid fiberoptic intubation (Bullard laryngoscope).
- Alternative Airways.

♦ May NOT be definitive airways.
♦ Allow for oxygenation and ventilation when standard airways cannot be placed.
♦ "Fastrach" model laryngeal mask airway (LMA).
♦ Esophageal-tracheal combitube (ETC).

When to expect a Difficult Airway?

The picture below represents pretty much a perfect airway. It is from an airway manikin and is labeled for anatomical structures.

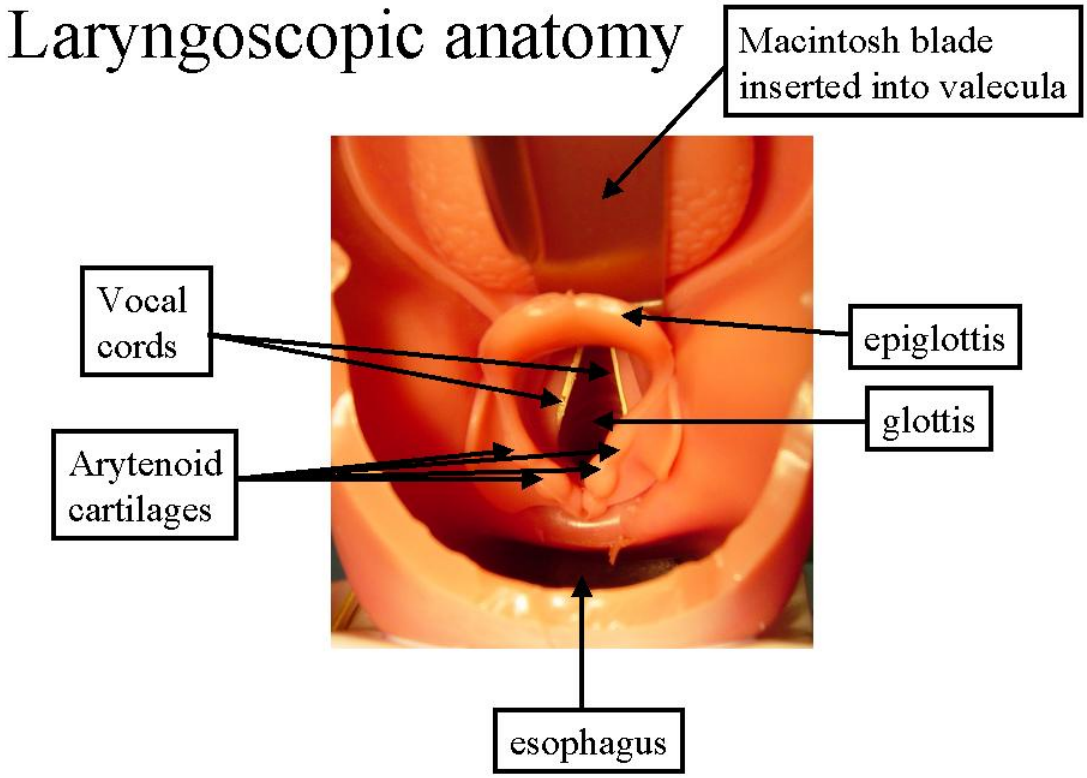

The American Society of Anesthesiologists have developed a system for recognizing a possible problem intubation. For prehospital care this is used primarily for Rapid Sequence Intubation and documentation of the patients airway when an RSI is performed.

However, it is also a great tool to use when documenting any intubation and should be used when ever possible. This will help EMS systems in creating more choices and better training guidelines for the future.

The following also discusses types of difficult airways. While not all directly related to EMS care. They demonstrate why you may have difficulties in the field with what would seem an otherwise normal endotracheal intubation.

Prediction and Management of Difficult Tracheal Intubation

Introduction

During routine ETI the incidence of difficult tracheal intubation has been estimated at 3-18%.

Difficulties in intubation have been associated with serious complications, particularly when failed intubation has occurred. Occasionally in a patient with a difficult airway, the paramedic is faced with the situation where mask ventilation proves difficult or impossible. This is one of the most critical emergencies that may be faced in the practice of emergency care. If the paramedic can predict which patients are likely to prove difficult to intubate, he may reduce the risks of ETI considerably. The following reviews clinical techniques used for predicting difficulties in intubation and suggests different approaches to manage these patients.

There have been various attempts at defining what is meant by a difficult intubation. Repeated attempts at intubation, the use of a bougie or other intubation aid have been used in some papers, but perhaps the most widely used classification is by Cormack and Lehane which describes the best view of the larynx seen at laryngoscopy (figure 1).

Class I: the vocal cords are visible
Class II the vocals cords are only partly visible
Class III only the epiglottis is seen
Class IV the epiglottis cannot be seen.

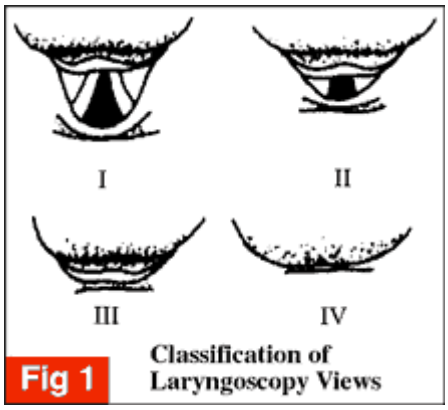

This should be recorded in the PCR whenever tracheal intubation is performed or attempted so there is a record for future use. Especially if Rapid Sequence Intubation is performed.

Predicting Difficult Intubation

Tracheal intubation is best achieved in the classic "sniffing the morning air" position in which the neck is flexed and there is extension at the cranio-cervical (atlanto-axial) junction. This aligns the structures of the upper airway in the optimum position for laryngoscopy and permits the best view of the larynx when using a curved blade laryngoscope. Abnormalities of the bony structures and the soft tissues of the upper airway will result in difficult intubation.

History and examination

Pregnant patients, those suffering from facial/maxillary trauma, those with small mandibles or intra-oral pathology such as infections or tumours are all more likely to present difficulties during intubation.

Patients who suffer with rheumatoid disease of the neck or degenerative spinal diseases often have reduced neck mobility making intubation harder. In addition spinal cord injury may result from excessive neck movements during intubation attempts. Poor teeth and the inability to open the mouth are obvious other factors as are obesity, and inexperience on the part of the paramedic.

Ways to Predict Difficult Intubation.

There a number of specific clinical assessments that have been developed to try to identify patients who will prove difficult to intubate. Mallampati suggested a simple screening test which is widely used today in the modified form produced by Samsoon and Young The patient sits in front of the paramedic and opens the mouth wide. The`patient is assigned a grade according to the best view obtained (figure 2).

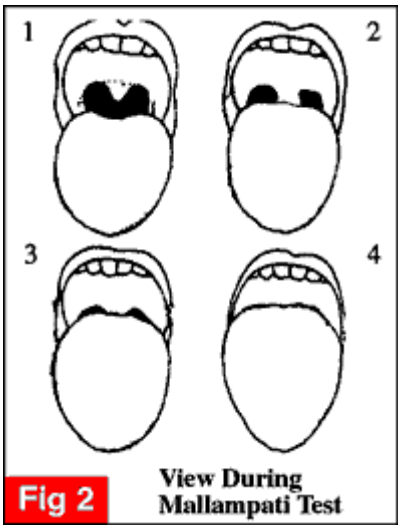

View obtained during Mallampati test:
1. Faucial pillars, soft palate and uvula visualised
2. Faucial pillars and soft palate visualised, but uvula masked by the base of the tongue
3. Only soft palate visualised
4. Soft palate not seen.

Clinically, Grade 1 usually predicts an easy intubation and Grade 3 or 4 suggests a significant chance that the patient will prove difficult to intubate. The results from this test are influenced by the ability to open the mouth, the size and mobility of the tongue and other intra-oral structures and movement at the craniocervical junction.

Thyromental distance

This is a measurement taken from the thyroid notch to the tip of the jaw with the head extended. The normal distance is 6.5cm or greater and is dependant on a number of anatomical factors including the position of the larynx. If the distance is greater than 6.5cm, conventional intubation is usually possible. If it is less than 6cm intubation may be impossible

By combining the modified Mallampati and thyromental distance, Frerk showed that patients who fulfilled the criteria of Grade 3 or 4 Mallampati who also had a thyromental distance of less than 7cm were likely to present difficulty with intubation . Frerk suggests that using this combined approach should predict the majority of difficult intubations. A 7cm marker can be used (eg a cut off pencil or an appropriate number of examiners fingers) to determine whether the thyromental

distance is greater that 7cm.

Protrusion of the mandible is an indication of the mobility of the mandible. If the patient is able to protrude the lower teeth beyond the upper incisors intubation is usually straightforward If the patient cannot get the upper and lower incisors into alignment intubation is likely to be difficult.

Before we discuss the surgical and blind intubation techniques. I want to focus on Trauma and how it can affect airway control.

AIRWAY IN TRAUMA PATIENTS

The most immediately life threatening complication of any trauma is loss of airway patency. Maintaining oxygenation and preventing hypercarbia are critical in managing the trauma patient, especially if the patient has sustained a head injury. Thus, the first step in evaluating and treating any trauma patient is to assess airway patency and, if compromised, restore it: the A of A (airway), B (breathing), C (circulation). Any patient who is awake, alert and able to talk has a patent airway. Whether they need supplemental oxygen can be determined by vitals and physical exam. Patients who are unconscious or have signs suggestive of respiratory compromise, however, require immediate attention.

All patients should be immobilized due to increased risk of spinal injury. Assessment of the patient should be done while maintaining the cervical spine in a stable, neutral position. Begin the primary survey by rapidly assessing airway patency: rapidly assess for obstruction. Maintain an airway with jaw thrust or the chin lift maneuver. Clear the airway of foreign bodies. If the patient is likely to vomit, position them in a lateral and head down position to prevent aspiration. All trauma patients should be administered supplemental oxygen!

Determine the patient's needs. Signs and symptoms suggestive or airway or ventilatory compromise include:

- maxillofacial trauma
- neck trauma
- laryngeal trauma (with hoarseness or subcutaneous emphysema)

LOOK for:

- obtundation
- agitation (which may suggest hypercarbia)
- cyanosis
- retractions/accessory muscle use
- symmetrical rise and fall of the chest wall

LISTEN for:

- abnormal breath sounds
- snoring
- stridor
- crackles
- dysphonia
- symmetrical breath sounds over both hemithoraces
- tachypnea

FEEL for:

- a deviated trachea
- subcutaneous emphysema

The ladder of tools available for respiratory support in order of increasing invasiveness are:

- Nasal cannula
- Face mask, nonrebreather face mask
- Nebulizer
- Oral-pharyngeal airway/Nasoparyngeal airway
- Bag-mask ventilation
- Intubation – Any patient exhibiting airway symptoms (stridor, hoarseness, severe cough, voice change) and all unconscious patients should be intubated.

  Endotracheal intubation is far superior to bag-mask ventilation because it provides larger tidal volumes and prevents aspiration. Particularly in the trauma patient population – often time obtunded or unconscious, with loss of or diminished gag reflexes – the prevention of aspiration is of key importance.

Emergency Cricothyroidotomy – When all else fails.

LANDMARKS AND PROCEDURE FOR NEEDLE CRICOTHYROIDOTOMY

1. Properly identify the cricothyroid membrane using external landmarks. (The cricothyroid membrane lies just above the cricoid cartilage.)
2. Locate the cricothyroid membrane:
    - a. By palpating the trachea just above the sternal notch and proceed upward until the prominence of the cricoid cartilage is identified
    - b. By palpating the thyroid notch and proceeding downward until the prominence of the cricoid cartilage is identified.
3. Palpate the junction of the trachea and the cricothyroid membrane which forms a "T", to insure proper identification of the cricothyroid membrane.
4. Stabilize the larynx with fingers of the non-dominant hand.
5. Cleanse the overlying skin with Povidone Iodine solution.
6. Introduce a 10-14 gauge over-the-needle catheter attached to a 3 ml syringe through the skin just above the cricoid cartilage at a 45° downward angle.
7. Advance the needle into the cricothyroid membrane and into the airway.
8. When air is aspirated, **stop** advancing the needle, advance the catheter over the needle into the trachea, and remove the needle.
9. Attach the barrel only of the 3 ml syringe to the over-the-needle catheter. Attach a 7.5 mm Endotracheal Tube adapter to the 3 ml syringe barrel.
10. Deliver oxygen at 15 lpm with a Bag-Valve-Device, or via <u>Intermittent Jet Insufflation</u> device capable of delivering oxygen at 60 psi with a timed cycle of 3 seconds "on" followed by 5 seconds "off", and an exhaust port.
11. Auscultate lungs for air entry.
12. Look for chest expansion, and check for **egress** of air.

Surgical Cricothyrotomy

Identify cricothyroid membrane (between cricoid ring and thyroid cartilage [Fig. 1-6a]).

Prep skin widely.

Grasp and hold trachea until airway is completely in place.

Make a vertical SKIN incision down to the cricothyroid membrane (a No. 10 or 11 blade).

Bluntly dissect the tissues to expose the membrane.

Make a horizontal MEMBRANE incision (Fig. 1-6b).

Open the membrane with forceps or the scalpel handle.

Insert a small, cuffed ETT, 6.0-7.0 inner diameter (ID), to just above the balloon (Fig. 1-6c).

Confirm tracheal intubation.

See next page for images

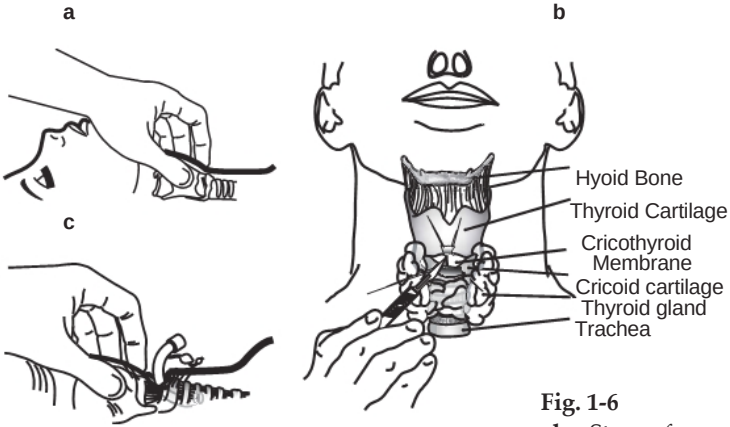

Fig. 1-6
a,b,c. Steps of surgicalcricothyrotomy.

Finally let’s cover the blind techniques you can use to secure an airway. While endotrachael intubation is the preferred method of airway maintanence. The following procedures are beneficial for difficult airways, and may be the method preferred by your service for certain situations.

Laryngeal Mask Airway

Do NOT use in penetrating upper airway trauma or central airway obstruction (foreign body).

Insert blindly without a laryngoscope. LMA rests over the laryngeal inlet (Fig. 1-7)

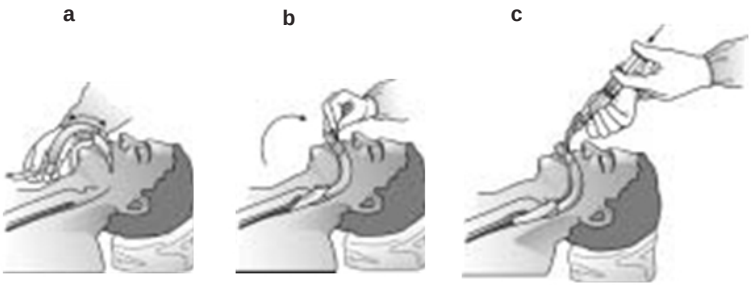

Fig. 1-7 a,b,c. Fastrach laryngeal mask airway placement. Illustration courtesy of LMA North America, Inc.

May be used alone or as a conduit to advance an ETT. Compared to an ETT, the LMA supports less airway pressures, and offers less aspiration protection.
Check LMA cuff, then deflate it until the down side (inner) surface is smooth and flat; lubricate the pharyngeal (upper) side of LMA.
The sniffing position works best, but LMA may be inserted in different patient positions.

 Insert LMA (3-4 for women, 4-5 for men) with upper (pharyngeal) side gliding along the hard palate, down and around into the posterior pharynx—this allows proper direction and reduces the chance of cuff folding.
 Do NOT push the LMA directly back into the mouth— this folds the cuff and prohibits proper placement.
 Inflate cuff with 20-30 cc of air via syringe—slight upward movement of LMA tubing is seen.
 Secure the LMA.

Blind nasal-tracheal intubation

Contraindications: Coagulopathy, midface trauma, basilar skull fracture, and suspected elevated intracranial pressure.

Nasal-trachael intubation is better tolerated than orotracheal techniques and requires less sedation and no paralysis.
Prepare the nasopharynx and larynx (as conditions allow).
 Spray vasoconstrictor into the nostril that appears largest and most patent.
 Insert a nasal trumpet soaked in lidocaine gel and leave in place for a brief period.
 Apply Cetacaine spray to oropharynx.
 Administer a transtracheal injection of 4 cc lidocaine via cricothyroid membrane.
Insert an ETT (~ 7.0 ID for adults) slowly into the nostril, perpendicular to the face.
Advance the ETT slowly past the nasal turbinates and around the curve of the posterior nasopharynx.
Do not use excessive force!

The ETT is advanced as breath sounds of increasing volume are heard at the distal end of the tube.
The ETT is advanced beyond the vocal cords into the trachea. If the tube fails to advance into the trachea, several maneuvers can be employed.
 Tilt the head.
 Apply external, downward pressure to the larynx.
 Inflate the ETT balloon to help center the tube, then deflate and advance it once it is engaged in the glottic opening.

A few quick tips for providing good airway management and control

Mask Ventilation: Wrong Size Mask for Face ? If you must mask ventilate (O2BVM) a small-stature adult or child with a typical "Adult Mask" which is larger than can readily seal on the patient's face, try inverting the mask so that the usual chin portion lies across the nation and cheek bones and the narrow nasal portion of the mask is used to fit against or around the chin; this may be sufficient adaptation to control the situation until an appropriately sized mask is available.

If the patient is edentulous and has sunken cheeks and hasn't the customary facial architecture to effectively seal the mask: try slipping a "Newborn Mask" in place and then into the patient's mouth. Use your support hand to "cup" the chin and pull upwards stabilizing the mask port within the "OK Sign" of your thumb and index fingers and pinch the nostrils closed. This should allow satisfactory seal and ventilation until a definitive airway can be placed.

An additional solution is to place a nasopharyngeal airway with an endotracheal tube connector in place to which the O2BVM can be attached. Support the chin and pinch the nostrils in the same fashion: continue until a definitive airway is placed. This works well for "One-Man" single-rescuer CPR until endotracheal intubation support arrives (the bag just hangs in place at the patient's nose during compressions, and ventilations can be given more quickly this way without changing positions or having to carefully fit a mask).

Head Suspended In The Air: Older, stiffer necks and those beset by arthritis, ankylosing spondylitis, rheumatoid arthritis, previous fusion of the cervical spine, or bodies deformed by kyphosis, scoliosis, gibbus or "dowager's hump", lack normal mobility and may have locked joints.

Inspect the patient's head, neck, and shoulders from the side looking for gaps in support. The stiffness may be sufficient that the unsupported head and neck is off the bed.

Support these areas by filling in "hollows" with padding or towels to prevent injury.

Consider neck injury if there has been trauma, even minor.

Anticipate potential "Difficult Airway - Difficult Intubation", especially poor visualization of the glottis or difficulty inserting the tube.
Mask Ventilation or laryngeal mask ventilation may remain satisfactory.

Avoid sedation and paralysis if there is potential for soft tissue airway collapse.

Consider potential need for an alternative airway, such as a Laryngeal Mask Airway, Esophageal Tracheal Combi-Tube, Illuminated Stylet or TrachLight, or Fiberoptic Bronchoscope.

Bony changes in the thorax and weakness of thoracic muscles may constitute restrictive lung disease predisposing to respiratory insufficiency and pneumonias. Such patients may be difficult to wean from the ventilator.

Overshoot to Mainstem Bronchus: A common error by the intubator is to insert the endotracheal tube too far past the vocal cords with the tube going into the Right Mainstem Bronchus, as it is more nearly in line with the trachea and is larger than the Left Mainstem Bronchus. This results in one lung ventilation and the possibility of barotrauma from the volume intended for two lungs being delivered to one. The unventilated lung will become progressively atelectatic and collapse. Unoxygenated blood from the left lung will mix with the output of the right lowering the amount of oxygen delivered to tissues.

The first clue in detecting this is to observe the length of tube outside the airway and checking the depth markings (~22 cm - 24 cm for oral; ~25 - 27 cm for nasal tubes in adults).

Next, observe the symmetry of chest wall expansion.

Third, auscultate the left axilla first, then the right axilla (comparing equality of breath sounds), then the stomach for gastric bubbling indicating esophageal intubation.

Oximetry and capnography should be present, but will not show immediate change if one lung ventilation occurs.

Tube depth may need to be adjusted.

If concerned about the depth of the tube and adequacy, always consider seriously whether esophageal placement has occurred. Use every objective test available, as well as clinical findings, until you can confirm unequivocally that the tube is in the trachea and the right depth and adequate ventilation is occurring. "If in doubt, take it out."

Trismus/ Bitten Tube: **Trismus**, the inability to open the mouth normally, can be due to seizure, anoxia, muscle spasm, tetanus and other infections, trauma, radiation injury, or inflammatory conditions of the TMJ, and can significantly impede the management of the airway.

Initial management is a well fitting mask, taking care to ensure that the lips are parted to allow ventilation between and around the teeth as well as the nose.

Neuromuscular blockade and deepening the induction sedative may cause relaxation if due to tetanic contraction of muscles, but cannot alter damaged tissue, e.g., scars and contractures, locked joints., etc.

Laryngeal mask airways can often pass if there is 20 mm of inter-dental opening.

Nasotracheal intubation can be tried, perhaps with fiberoptic assistance. If possible, use a nasal decongestant and vasoconstrictor first, lubricate generously, be careful and gentle so as to avoid epistaxis that may worsen the problem.

If the patient is orally intubated but is inadequately sedated and paralyzed, or undergoes spasm or seizure, the tube can be occluded by bite pressure or even severed if a bite block is not in place or the patient is not immediately paralyzed of anesthesia deepened. A gauze roll or plastic bite stick may be used to prevent complete occlusion of the tube.

Mask-Tegaderm Over Stoma: If a patient with an open stoma needs respiratory support, the stoma will either be a leak if ventilated by face mask from above, or an opportunity through which to ventilate the patient by a soft-cuffed mask

or through which to pass a cuffed tube by which to isolate the lower airway and ventilate the patient.

If the contour of the neck is irregular (from surgery or radiation) and mask fit is poor, or the upper airway (mouth and nose) are too great a leak, or the tracheostomy is healing and nearly closed (difficult to ventilate or cannulate, but still a leak) ,one may feel more confident performing conventional face mask ventilation. The stoma can be occluded for this by covering it with a Tegaderm®/Op-Site® type dressing. Be careful to confirm adequate ventilation by face mask by checking for adequate chest excursion and auscultation of breath sounds.

Short Jaw: Mask ventilation may require jaw lift (triple airway maneuver), use of both hands to hold the mask, or insuring good cuff seal of the mask against the face. Cricoid pressure may help visualize the cords. May need a straight blade or a short blade to lift only the jaw. A "hockey-stick" angulation of the tube on the stylet may be necessary to help enter the larynx. Transilluminated intubation may work well. Laryngeal Mask Airway.

Unconscious Patients Trapped or Sitting Up : Primarily for Trauma patients. Laryngoscopic Intubation From The Front: "The technique is very simple. Have someone maintain C-spine immobilization (collar can be in place or not), have plenty of O2 on board, make sure sat is 100%, then using the Mac just hook it into the mouth and pull straight forward. Look in and Voila!

The person controlling C-spine should be experienced and know what s/he is doing. Must be very careful not to let it move. If done right, the only movement will be the mandible, which will simply be jutted as in the jaw thrust."

Some of the following information has been included earlier in this report. We have included the following Glossary to have all the airway terms in one place for easy reference.

AIRWAY GLOSSARY

Airway

A generic term covering anything from the lips to the alveoli, although often divided into the upper airway (oral cavity, glottis, trachea) and the lower airway (bronchi down to alveoli). The airway is the top priority in all clinical emergencies, as in the following generic priority sequence:

(1) Airway
(2) Breathing
(3) Circulating
(4) Drugs

Airway Burns

Singed nose hairs or nasal soot in patients who have suffered burns elsewhere makes the wise clinician suspicious for airway burns. Such patients may develop airway edema that could be life-threatening and that requires intubation to ensure a secure airway. The airway damage can best be assessed by fiberoptic bronchoscopy (principally looking for airway edema). Carbon monoxide levels should be measured in all such patients and 100% oxygen should be given to drive off

the carboxy molecules from the hemoglobin binding sites.

Airway Obstruction

Airway obstruction frequently occurs following the induction of general anaesthesia. Traditionally this has been attributed to the tongue falling back against the posterior pharyngeal wall (and is remedied by placing an appropriately sized oropharyngeal airway). Recent studies suggest that obstruction by the soft palate or epiglottis from reduced airway tone may also be responsible. Hypoventilation may result from airway obstruction, leading to hypercarbia and then hypoxemia.

Airway obstruction can also occur from airway edema (e.g., following extensive head and neck surgery or anaphylaxis), from airway infections (e.g., epiglottitis), from airway tumors(laryngeal papillamotosis), or from foreign bodies (e.g., aspirated hunk of steak).

Alveolar Ventilation ()

This is the volume of gas per minute that takes part in gas exchange

= (VT - VD) x f

where VT is the tidal volume, VD is the respiratory deadspace, and f is the breathing rate (respiratory frequency). Alveolar ventilation may be reduced with airway obstruction or low respiratory rates (such as are encountered with excessive doses of narcotic analgesics such as morphine). Reduced alveolar ventilation leads to hypercarbia, and possible hypoxemia. Hypoxemia due to hypoventilation is far less likely when the patient is receiving oxygen.

Apnea

Complete cessation of breathing. Obviously apnea must be managed promptly to avoid hypercarbia and hypoxemia. Ultimately, apnea leads to cardiac arrest preceeded by bradycardia (usually).

ARDS (Adult Respiratory Distress Syndrome)

ARDS is a sometimes deadly lung problem following trauma, aspiration pneumonitis and countless other clinical insults, resulting in small, stiff, hard-to-ventilate lungs. This deadly respiratory condition is often frequented in the ICU, with ventilators straining away to push gas into small stiff lungs.

The syndrome histologically is similar to respiratory disease of the premature newborn (RDS), hence its name, but rather that resulting from pulmonary

immaturity, ARDS is the consequence of many clinical insults, aspiration pneumonitis, massive trauma, and septicemia being common examples.

An important part of ARDS therapy is to distend the lung to make it bigger so that more alveoli are open. This is done using PEEP (Positive End Expiratory Pressure), a technique where the airway pressure waveform is maintained positive (e.g., 10 cm H2O) even during expiration. PEEP therapy impairs venous return to the heart, making it problematic in hypovolemic patients.Another problem with ARDS is leaking pulmonary capillaries that may lead to pulmonary edema. This necessitates careful fluid management and sometimes requires that PA line monitoring (Swan-Ganz catheter) be used.

ARDS carries with it three management issues:

oxygenation
ventilation
fluid management
intubation

Oxygenation
The high degree of pulmonary shunt present is ARDS necessitates that two ventilator parameters (FIO2 and PEEP) be adjusted upward jointly to achieve adequate oxygenation (eg. SaO2 > 0.9 of PaO2 > 60 mmHg). Fio2 is the fraction of inspired oxygen (eg. 0.5 for 50% oxygen). PEEP is the Positive End Expiratory Pressure

of minimal lung distending pressure (eg. 5 cm H_2O). FIO_2 and PEEP are not adjusted independently but rather jointly, even sometimes by quantitative linking (eg. PEEP = 15 FIO_2). Patients that are hypovolemic may tolerate PEEP less well and require less strong linkage to FIO_2.

Ventilation

Ventilation may be difficult in ARDS patients since high ventilating pressures are required to achieve normal tidal volumes. The high ventilating pressures required are suspected to be a cause of more lung injury, leading some researchers to advocate the use of "permissive hypercapnia" a ventilating protocol allowing higher PCO_2 levels ad more acidotic pH levels but with much smaller tidal volumes and airway pressures, and less potential for barotrauma. Special ventilation modes such as inverse ratio ventilation (EI ratio < I), airway pressure release ventilation, and high frequency jet ventilation.

Fluid Management

ARDS has associated with it increases in vascular permeability (leaky capillaries) that mandates special care regarding fluid management. Hypovolemia can be avoided by monitoring urine output and cardiac filling pressures (CVP, PCWP).

Intubation

Patients with ARDS require intubation. High cuff pressures, required when high ventilating pressures are used, may damage tracheal mucosa and cause long

term injury (eg. Tracheal stenosis from scarring). After 10 to 14 days of intubation, consideration is given to a formal tracheostomy. Tracheal suction is also needed to avoid buildup of secretions. Reintubation of patients with ARDS may be necessary because of cuff leaks or because of the buildup of hardened secretions within the lumen of the ETT.

Aspiration

Refers to getting harmful debris [usually gastric in origin] into the lung's trachea and bronchi with the considerable potential to cause aspiration pneumonitis, a often deadly inflammatory reaction leading to ARDS. Aspiration pneumonitis is said to be more likely when the volume of aspirate exceeds 25 ml and when it has a pH under 2.5. Techniques to reduce the likelihood of aspiration with ETT insertion include (1) pharmacological adjuncts such as gastric motility agents, (2) use of awake intubation (airway reflexes remain intact), and (3) use of a rapid sequence induction technique employing preoxygenation, predetermined drug doses and cricoid pressure.

Asthma Treatment

Medications used in asthma management include:

Beta-agonists
Theophylline products
Corticosteroids

Anti-cholinergic medications
In addition, number of anaesthetic agents (eg. halothane, ketamine) have a salutory effect in asthma.

Inhaled Beta-adrenergic agonists such as albuterol (salbutamol), terbutaline, fenoterol, pirbuterol or salmeterol remain the mainstay of treatment; although, their role in the chronic treatment of asthma is in a flux, with many clinicians preferring the use of inhaled corticosteroids as first-line therapy and with beta-agonists reserved for "prn" use.

Intravenously administered theophylline products such as aminophylline are waning in clinical popularity since they have a very poor toxic/therapeutic index and do not add significant clinical benefit in patients already receiving beta-agonists for an acute exacerbation of asthma. Its main role is not in preventing acute attacks in the chronic asthmatic, especially at night. In patients with COPD, improvements in diaphragmatic function and in muco-ciliary clearance make Theophylline a useful adjunct as well.

Corticosteroids are now taking on a new importance in treating patients with reactive airways disease (RAD) as the inflammatory element in RAD is more appreciated. Inhaled corticosteroids are now often used as first-line asthma therapy while intravenous steroids are often used preoperatively in patients in with moderately severe asthma or in those previously requiring steroid therapy. However, in contrast to beta-agonists, whose

clinical effect is almost immediate, IV steroids take several hours to work.

Awake Intubation

The process of inserting an endotracheal tube (ETT) through a patient's vocal cords into his or her trachea while the patient is conscious. Patient cooperation is far more easily achieved by using local anaesthesia or nerve blocks (for example, using lidocaine in a dose not exceeding 5 mg/kg). Awake intubation has the advantage that the anesthetist can always "back off" if intubation becomes difficult, and no bridges have been burned by giving potent, potentially dangerous drugs to the patient (e.g. succinylcholine). Awake intubation is often carried out without drugs in newborns with aspirated meconium (fetal feces) or in adults who are moribund. Otherwise local airway anesthesia should be used.

"Bail-Out" Algorithm (to awaken patient after failed intubation)

A strategy used when mask ventilation is becoming difficult following the induction of general anesthesia complicated by unsuccessful intubation. This is a setting where you want the patient to wake up and breath spontaneously.

1. Ensure that the patient is not in laryngospasm and that the patient's head and jaw are positioned properly. Call for help.

2. Insert an airway of some kind

A - oral airway

B - nasopharyngeal airway

C - LMA (Laryngeal Mask Airway)

WARNING: Airway insertion may lead to laryngospasm in lightly anesthetized patients

3. Utilize a two-person technique whereby one person manages the mask and holds the jaw in position using both hands, while the other ventilates the patient by hand using the rebreathing bag.

4. As a last resort, a surgical airway (TTJV, cricothyroidotomy) is sometimes necessary.

Bradypnea

Decreased breathing rate, usually under 10 breaths per minute. This is often due to the administration of narcotic analgesics such as morphine, meperidine or fentanyl. Other causes may include increased

intracranial pressure (eg from brain tumor). You should know the differential diagnosis of bradynea.

Can't Intubate Algorithm

This clinical algorithm applies when the the patient cannot be intubated (but can be ventilated adequately with bag/mask/valve resuscitator apparatus)

1. Wake the patient up and proceed with awake intubation

OR

Insert ILM and then an ETT via the ILM (keep patient asleep)
OR
Use Syracuse-Patil face mask to facilitate fiberoptic intubation (keep patient asleep)

REMEMBER TO CALL FOR HELP

Can't Ventilate Algorithm (patient intubated)

Remember differential diagnosis:
ETT problem (e.g. kinked ETT, ETT plugged with secretions),
Patient problem (e.g., bronchospasm, pneumothorax)
Ventilator / anesthesia machine problem

2. Administer 100% O2; Check airway pressure and listen for wheezes and equal air entry bilaterally.

3. Rule out an ETT problem by passing an ETT suction catheter through the ETT after disconnecting from the patient breathing circuit.

Rule out a ventilator problem by hooking up the ETT to a manual resuscitator (Ambu, Laerdal) instead of the automatic ventilator. Ventilation should be easy.
If it is a patient problem, then consider such possibilities as bronchospasm or airway collapse according to the available clinical data. Collect information about ventilator settings, airway pressure parameters (peak airway pressure, PEEP), the equality of air entry on both sides, the presence of crackles or wheezes on auscultation or factors such the use of a bronchial blocker (for one-lung ventilation) or the presence of an aspirated foreign body (e.g. aspirated peanut) or a pneumothorax (e.g. following CVP line insertion)
REMEMBER TO CALL FOR HELP

Cormack and Lehane Grading of View at Laryngoscopy

grade I - complete glottis visible
grade II - anterior glottis not seen
grade II - epiglottis seen, but not glottis
grade IV - epiglottis not seen
Grades III and IV are termed "difficult intubation"

Dead Space (VD)

Volume of gas delivered to the patient in inspiration that does not participate in gas exchange. VD may be estimated using the Bohr equation

where VT is the tidal volume, P_{ECO_2} is the mixed expiratory carbon dioxide tension, and P_{aCO_2} is the arterial carbon dioxide tension.

Difficult Intubation (DI)

A situation where the patient is known or expected to be difficult to intubate using standard laryngoscopes. Such cases are often managed using a fiberoptic bronchoscope or Bullard laryngoscope to facilitate ETT placement, often with the patient awake.

Dyspnea

Shortness of breath.

Early Morning Sniffing Position

A patient head position that facilitates intubation by lining up the oral, pharyngeal and laryngeal axes. In the "sniffing position" the neck is flexed while the atlanto-occipital joint is extended. Placing a pillow under the shoulders and head to maintain this position is often helpful.

Endotracheal Tube (ETT)

A "breathing tube", often with a cuff at the distal end, allowing a sealed leak-free connection between a ventilator and a patient's trachea. Such an arrangement allows both positive pressure ventilation and spontaneous breathing. Typically, a size 7.5 (7.5 mm inner diameter) is used for adult women, with a size 8.5 for men. In some centers it is customary to cut the ETT prior to use (e.g. oral ETTs: women - cut at 23 cm; men - cut at 25 cm). The ETT cuff pressure should be kept below 25 cm H2O to prevent injury to the tracheal mucosa.

Specialized ETTs are available where ETT kinking is a concern, for special kinds of surgery (ENT surgery, laser surgery) or where one-lung ventilation is needed. Uncuffed tubes offer reduced protection against aspiration and are used in preadolescent children according to the following approximate guidelines:

ETVC Endotracheal Ventilation Catheter (Tube Exchanger)

A device used to facilitate reintubation following a trial of extubation. Prior to extubation the ETVC is placed into the ETT and the ETT withdrawn over it holding the ETVC in place. If reintubation becomes necessary the ETVC can be used as a guide to direct the new ETT through the cords. The ETVC can also be used to administer low flow oxygen deep into the lungs (eg. 2 l/min flow rate) as well as for capnography or even emergency jet ventilation in a manner similar to TTJV.

Extubation

The process of removing an ETT from the patient's trachea. This should ordinarily only be done with the patient awake and obeying verbal commands. Even so, catastrophies on extubation can occur, such as total collapse of the airway in a patient with tracheomalacia. Sometimes it is wise to extubate over an ETT exchange catheter.

Extubation Guidelines

1. Patient should be fully awake

2. Airway tone should be recovered with cough and gag reflexes intact

3. An ETVC should be employed if appropriate (difficult intubation patients)

4. Technical criteria should be satisfied in patients with poor respiratory function.

(a) Patient can maintain adequate oxygenation

(b) VC > 15 ml/kg

(c) NIF > 20 cm H2O

Facial Trauma

Victims of facial trauma may succumb from airway edema or loss of airway structural support. Intubation may be difficult in patients with Lefort I or II fractures (which puts bony fragments in the nasal airway). Oral intubation may be difficult because of trismus or even because of bizarre things such as a knife impaled into the neck. Furthermore, intubation may be complicated by distortions in the anatomy due to trauma or hematoma formation. Sometimes fiberoptic intubation works with such patients, but not if the airway is very bloody (poor view). Sometimes a tracheostomy under local anaesthesia is needed.

Head Trauma

Blunt and penetrating head trauma victims from motor vehicle accidents often require intubation to allow therapeutic hyperventilation to reduce cerebral edema. A PaCO2 level between 28 and 32 mmHg is often sought. In addition, these patients may need intubation simply to protect the airway against aspiration, as the patient's gag reflex may be obtunded from the head injury.

Hypoventilation

Ventilation inadequate to the body's metabolic needs, so that hypercarbia results.

Laryngeal Mask Airway (LMA)

A relatively new method of airway management that has become extremely popular in Europe (and to a lesser degree in North America). The LMA is a device that is seated over the glottis with the epiglottis often sitting in its bowl. Advantages of the LMA over the ETT include: ease of insertion, less stimulating to the airway and reusability. The main disadvantage of LMA is that it does not protect against aspiration or laryngospasm.

Laryngoscope

An instrument to provide illumination to the glottis so as to facilitate passing an ETT through the patient's vocal cords. Of course, laryngoscopes are also used to examine for any pathology (edema, bleeding, polyps, fibrosis). The most popular laryngoscope, the Macintosh design, is curved so that the end fits into the vallecula, lifting the epiglottis out of the way to expose the vocal cords. Special laryngoscopes also exist, such as the straight blade (Miller) design (passed posterior to the epiglottis, avoiding the vallecula, and the Bullard laryngoscope, often very helpful when mouth opening is quite limited.

Laryngoscopy

The art and science of viewing the larynx. First achieved indirectly using mirrors in the middle 1800s, direct laryngoscopy followed in the late 1800s / early 1900s to allow tracheal intubation. When laryngoscopy is performed for diagnostic or therapeutic purposes under general anaesthesia (eg. by propofol infusion) one's goals are to provide for relaxation of the jaw muscles and vocal cords during the procedure, with subsequent recovery of the laryngeal reflexes without incurring the wrath of laryngospasm. More commonly, however, laryngoscopy is carried out to allow intubation.

Management of Laryngospasm

Laryngospasm, the reflex closing of the glottis by the glottic musculature, is a protective mechanism provided by evolution that sometimes makes airway management difficult. Laryngospasm may occur from airway irritation such as might occur following excessive instrumentation of the airway or with secretions and blood irritating the vocal cords at light planes of anesthesia. Full laryngospasm may make ventilation impossible, at least until the muscles relax from the resulting severe hypoxia. While applying sustained positive pressure or deepening the anaesthetic with IV lidocaine or propofol, are sometimes effective in breaking laryngospasm, I prefer to use small doses of succinylcholine (as little as 10 mg will often do) to break laryngospasm when necessary. Always inspect inside the mask and mouth if laryngospasm occurs - sometimes laryngospasm is the first sign that the patient has aspirated some gastric contents.

Obesity

Obese patients are at increased risk of obstructive sleep apnea. Very obese patients may be difficult to intubate and even more difficult to ventilate after induction of anaesthesia, since anesthesia often leads to decreased muscle tone in the upper airway. This, in conjunction with redundant folds of oropharyngeal tissue, often leads to the tongue, soft palate and/or epiglottis obstructing the airway. Obese patients are also more prone to hypoxemia because of their small FRC and heavy chest wall.

Positive Pressure Ventilation (PPV)

The process of forcing gases down a patient's trachea using either a manual control technique or using an automatic ventilator. PPV can be done using a manual resuscitator or the rebreathing bag on the anaesthesia machine. But for long cases it makes more sense to use an automatic ventilator.

Pulse Oximetry

Since the commercialization of pulse oximetry two decades ago, thousands of lives have been saved by early detection of patient hypoxemia. Using the technologies of infrared spectroscopy and microprocessor-based signal processing, the pulse oximeter provides an indication of tissue oxygenation on an ongoing basis with a simple little finger probe not much bigger than a clothespin. Although pulse oximeters suffer form many pitfalls (eg. poor signals when patients are cold or vasoconstricted) they are an essential component to patient monitoring. No elective case should be started without a pulse oximeter. Pulse oximeters indicate the arterial blood saturation ie, the degree to which arterial blood hemoglobin binding sites are occupied with oxygen molecules. Patients are hypoxemic when arterial saturation falls under 90%.

Respiratory Compliance

A measure of the distensibility of the lung and chest wall, expressed as volume change per unit pressure change (ml/cm H2O)

Respiratory Failure

In its most basic form, PaCO2 too high or PaO2 too low.

Resuscitation

Resuscitation from cardiac arrest and other deadly situations often requires intubation both to supply high concentrations of oxygen and ventilate off carbon dioxide, as well as to protect the airway from being soiled by gastric contents.

Retrograde Intubation

Retrograde intubation involves passing a guidewire out the mouth via a puncture through the cricothyroid membrane. The guidewire is then strengthened by loading a sheath over it and passing an ETT into the trachea using the sheath as a guide. It offers special potential as a means of awake intubation in locations where fiberoptic intubation is unavailable (eg. third world countries).

Spontaneous Ventilation (SV)

Breathing using diaphragmatic +/- intercostal muscles. The diaphragm is innervated by C3 C4 C5 , so high cervical injuries are sometimes incompatible with SV and these patients may need diaphragmatic pacemakers for survival. SV can be disturbed in many ways: obstructive sleep apnea, airway infections (eg. epiglottitis), trauma to the airway etc. In such cases the use of positive pressure ventilation (PPV) may sometimes help.

Syracuse-Patil Face Mask

An anesthesia face mask with a side port for the introducion of a fiberoptic bronchoscope.

Tachypnea

Increased breathing rate. As lungs become stiff the patient finds it easier to take in smaller breaths and make up the difference with an increase in respiratory rate. Other causes may apply too, such as breathing in cardon dioxide in a bad rebreathing system, or sepsis syndrome. You should know the differential diagnosis of tachypnea.

Tidal Volume (VT)

Volume of gas delivered to the lungs during inspiration.

Transtracheal Jet Ventilation (TTJV - Needle Cricothyroidotomy)

In desperate circumstances injection of oxygen under high pressure directly into the trachea can be life-saving. This is done by inserting a #14 gauge IV catheter through the cricothyroid membrane and applying intermittent bursts of high-pressure oxygen through this catheter. A special nonkinkable needle for TTJV is available (Cook).

The original description of this technique, known as transtracheal jet ventilation (TTJV) suggested a 50 PSI pressure head, but clinical experience at this pressure shows that barotrauma (eg. pneumothoraces) are common at this pressure. A more reasonable amount might by 10 PSI; no one knows what the "best" choice is yet. Because of these concerns, many experts advocate the use of an emergency cricothyroidotomy kit. [Complications of TTJV include pneumothorax, pneumomediastinum, pneumopericardium, subcutaneous emphysema, esophageal perforation and infection.

Ventilators

Ventilators are used in operating rooms and intensive care units (ICU) for respiratory support of patients who cannot breathe on their own. ICU ventilators are more complicated and more flexible than OR ventilators. There are 5 main ventilator parameters.

Main Ventilator Parameters

1. Tidal Volume (eg. 700 ml) [Volume of gas injected into trachea with each breath]

2. Respiratory Rate (eg. 12 breaths/minute)

3. FIO2 (Fraction of Inspired Oxygen) (eg. 0.6 or 60% oxygen)

4. PEEP (Positive End Expiratory Pressure) (eg. 5 cm H2O)

5. I:E ratio (eg. 1:3)

Time for inspiration in relation to time for expiration

AIRWAY-RELATED ABBREVIATIONS

ABG Arterial Blood Gases
CVP Central Venous Pressure
DLT Double Lumen ETT
ETT Endotracheal Tube
ICU Intensive Care Unit
ILM Intubating Laryngeal Mask
LMA Laryngeal Mask Airway
PaCO2 Arterial carbon dioxide level
PaO2 Arterial oxygen level
PEEP Positive End Expiratory Pressure
PPV Positive Pressure Ventilation
SaO2 Arterial oxygen saturation
TTJV TransTracheal Jet Ventilation

Don't forget that you can also get the absolute meat and potatoes of EMS study by using EMS SEO "Quick Study Guide"
Now available in paperback.

Visit - http://emsseo.com/review